

Nasoalveolar Molding Treatment for a Patient With Amniotic Band Syndrome: A Case Report

Fırat Öztürk, DDS, PhD;¹ Erdem Hatunoğlu, DDS, PhD;^{2,*} Oğuzhan Altun, DDS, PhD³

ABSTRACT

Amniotic band syndrome (ABS) is an uncommon congenital malformation characterized by clubfoot deformity, hand and finger anomalies, and cleft lip and palate. In this study, the literature about ABS—possible etiology, treatment protocols, and medical procedures—is discussed. The aim of this study was to evaluate efficiency of nasoalveolar molding therapy for a patient with cleft lip and palate and ABS. Changes were evaluated before, during, and after the treatment period using a three-dimensional surface imaging system.

KEY WORDS: 3dMD, Amniotic band syndrome, Cleft lip and palate, Nasoalveolar molding

INTRODUCTION

Amniotic band syndrome (ABS) is a congenital disorder that is caused by fetal parts becoming entrapped in fibrous amniotic bands *in utero*. As the fetus grows, these bands begin to tighten, causing compressed blood circulation that can lead to autoamputation of extremities *in utero*.¹

Amniotic band syndrome causes some congenital abnormalities, such as cleft lip and palate (CLP), clubfoot deformity, and hand and finger anomalies, most frequently in the middle fingers (II, III, and IV) and particularly prevalent in the distal aspects of the extremities.² Additional abnormalities that are characteristic of ABS include syndactyly, progressive lymphedema, phalangeal hypoplasia, and limb-length discrepancies.² Cardiac and visceral malformations and brain and renal anomalies have also been reported in the literature about ABS, although these probably represent coincidental findings.^{3–5}

The severity of the defects that result from ABS relate to the location of the bands and the timing of the rupture.^{6,7} Weinzwieg⁸ has classified ABS according to whether it is deep enough to cause lymphedema or amputation. This classification involves four steps, the first step being mild

constriction without lymphedema and the final step including intrauterine amputation.

ABS is also known as amniotic deformity, adhesion, mutilations (ADAM) complex, amniotic band sequence, Streeter dysplasia, congenital constriction bands, and pseudoainhum. The syndrome is uncommon and generally has no relationship to any genetic or hereditary origin.² The etiology and risk factors related to it are also poorly understood. However, some studies have found prenatal risk factors associated with ABS, including prematurity (<37 weeks); low birth weight (<2,500 g); and illness, drug exposure, and hemorrhage/trauma during pregnancy.⁴

The incidence of ABS is not precisely known, but the literature reports that the syndrome occurs in between 1/1200 and 1/15,000 live births and does not differ between the sexes.⁹ Infants of young (<20 years old), black multigravidas show the highest prevalence.¹⁰

The treatment protocol for ABS is complex and includes multiple treatment processes, such as orthodontic, ophthalmologic, and orthopedic appli-

***Corresponding author:** Erdem Hatunoğlu, Fırat Üniversitesi, Diş Hekimliği Fakültesi, Ortodonti Anabilim Dalı, Elazığ, Turkey. Tel: +905053597991 E-mail: erdemhatunoglu@hotmail.com

To cite this article: Öztürk F, Hatunoğlu E, Altun O. Nasoalveolar molding treatment for a patient with amniotic band syndrome: a case report. *Turkish J Orthod.* 2014;27:112–117 (DOI: 10.13076/TJO-D-14-00026) Date Submitted: August 2014. Date Accepted: November 2014. Copyright 2014 by Turkish Orthodontic Society

¹Associate Professor, Department of Orthodontics, University of Pamukkale, Denizli, Turkey

²Assistant Professor, Department of Orthodontics, University of Fırat, Elazığ, Turkey

³Assistant Professor, Department of Oral Diagnosis and Radiology, University of Inonu, Malatya, Turkey

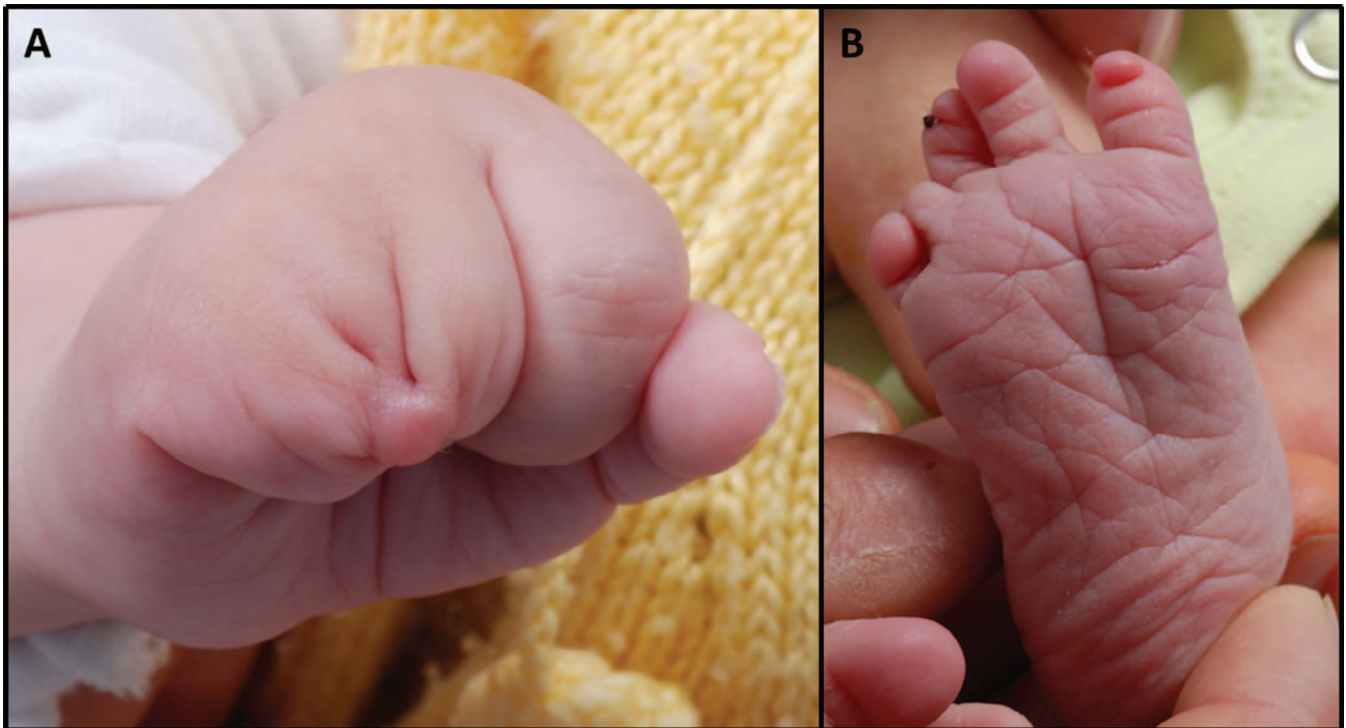

Figure 1. (A) Deficiency of right III, IV, and V fingers. (B) Constriction rings on the right foot.

cations; plastic and reconstructive surgeries; and speech therapy. Orthodontic treatments are particularly important for patients with CLP in the early stages.

We present the case of a patient with CLP and ABS. Changes were evaluated before, during, and after the treatment period using a three-dimensional surface imaging system (3dMD).

PATIENT AND MATERIAL

A 2-day-old female newborn patient was brought to our clinic with a left-side CLP and ABS. The patient had been delivered by cesarean section in the 40th week of pregnancy and had weighed 3250 g. She is the second child, and this was her mother's second pregnancy (the other child was healthy). The patient is a twin; her twin brother was born at 3500 g and has no systemic or hereditary problems.

Neither the mother nor the father (30 years old) of the patient had any systemic disease or hereditary anomalies. The mother had no trauma history and did not take drugs, smoke, or drink alcoholic beverages during the pregnancy. Her previous pregnancy had no problems, and the baby did not have low birth weight or any birth anomaly. In addition, no incidences of CLP were identified in the immediate family or among close relatives. The

patient's mother had been under the regular care of a physician throughout the pregnancy, and at the fourth month CLP was found through a routine ultrasound examination. However, nothing relating to ABS was indicated throughout the pregnancy.

The first examination after birth showed that fingers III, IV, and V on the infant's right hand were missing, and there were anomalies in the formation of the right toes and a unilateral left cleft lip and complete cleft palate (Figs. 1 and 2). Diagnostic records were taken before treatment (T1) and in the first month (T2), fifth month (before surgery) (T3), and sixth month (after surgery) (T4) of treatment. Diagnostic records contain 3dMD records, photographs, and dental casts (Figs. 2 through 4).

Presurgical Nasoalveolar Molding

After the first examination and when diagnostic records had been obtained, we applied a nutrition plate to help with feeding and maxillary development. This plate also inhibits the tongue from sticking in the cleft area, which prevents the cleft edges from being pressed apart and allows the tongue to rest as naturally as possible on the palate, providing appropriate stimulation for growth.

The nutrition plate was inserted for permanent use, except for cleaning, and this treatment protocol was continued until the gap between the maxillary alveolar

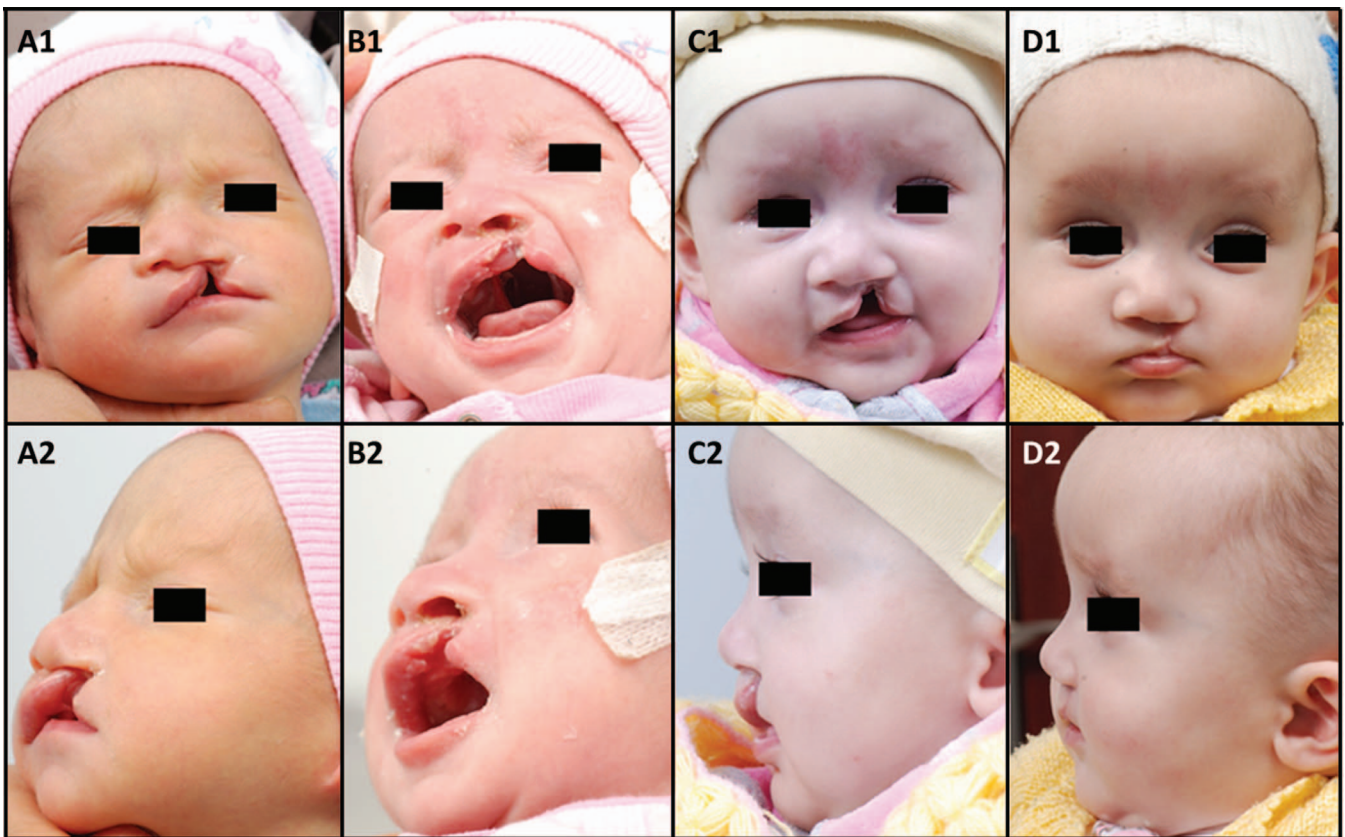


Figure 2. Front (A1, B1, C1, and D1) and lateral (A2, B2, C, and D2) views of the face showing the left-side cleft lip (A, B, C, and D represent treatment T1, T2, T3, and T4, respectively).

segments measured <5 mm. The gap was reduced by making additions or deletions on the plate, which redirects the forces of natural growth. Nasoalveolar molding (NAM) therapy was applied after the alveolar cleft gap was reduced to ≤ 5 mm, because an attempt to correct the nasal cartilage deformity in a larger alveolar cleft defect may result in an undesirable increase in the circumference of the lateral wall.¹¹

This period lasted 4 weeks, after which we started NAM therapy to form the structures of the nose and

lips. In cases of CLP, the nasoalveolar structures have some deformations; the patient's cleft-sided ala nasi and the tip of her nose appeared extremely sunken, and the length of the columella was decreased. During the treatment period, elastic bands and the nasal stent and alveolar molding plates were adjusted to achieve nasal and alveolar symmetry, nasal tip projection, and contact of the cleft alveolar segments. The treatment lasted 6 months, and the patient then had surgery on the nose and lip areas.

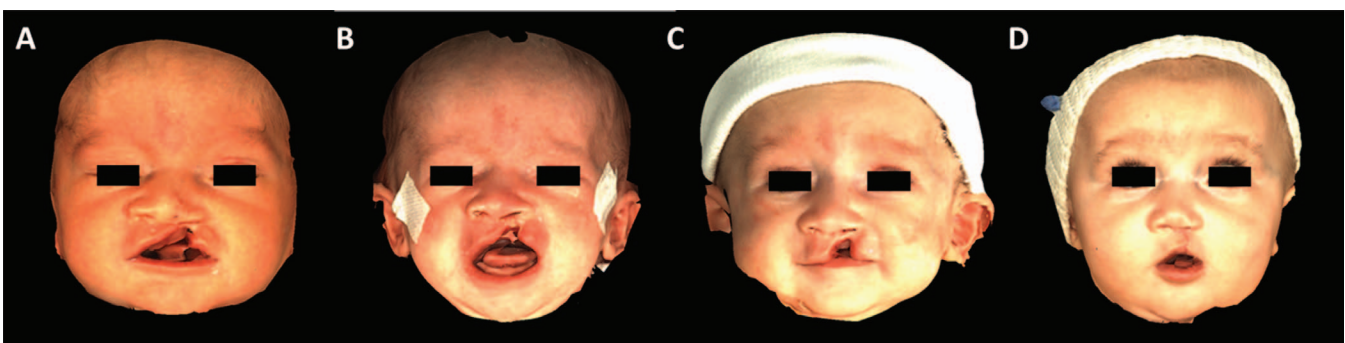


Figure 3. Three-dimensional surface imaging system images (A, B, C, and D represent treatment T1, T2, T3, and T4, respectively).

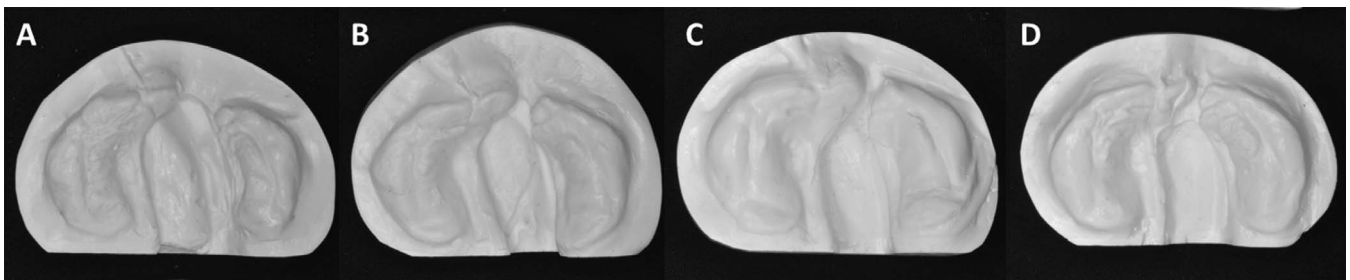


Figure 4. Serial maxillary alveolar casts showing reduction in the alveolar cleft gap and correction of alveolar arch form.

Dental Cast and 3dMD Records and Measurements

In this study, we evaluated the facial structures using the 3dMD system (3dMD, Inc, Atlanta, GA, USA). This system is particularly suitable for infants because it is noninvasive and nonionizing and offers rapid image acquisition and a digital format.¹²

The 3dMD images were taken when the infant was in a resting position, seated on a parent's lap, and arranged in the best position. The images obtained were recorded as TSB files and then transferred to 3dMD Vultus (3dMD Inc) software for soft tissue analysis.

We determined 17 well-described anthropometric landmarks identified by Farkas¹³ on each 3dMD image (Fig. 5); 5 linear and 6 angular measurements were made on the 3dMD images, and 2 linear measurements were made on the dental casts (Figs. 4 and 5). These linear and angular measurements were as follows.

Dental casts linear measurements:

1. Width of alveolar gap (distance between alveolar cleft borders; width of palatal cleft)

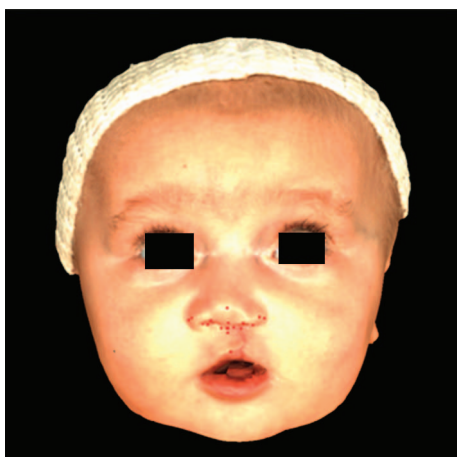

Figure 5. Facial landmarks used in this study for soft tissue analysis of the nasoalveolar region.

2. Width of palatal cleft (distance between cleft borders in anteroposterior midst of hard palate)

3dMD linear measurements:

1. Length of right columella (snr-cr)
2. Length of left columella (snl-cl)
3. Length of right ala (acr-prn)
4. Length of left ala (acl-prn)
5. Width of right nostril floor (sbalr-snr)
6. Width of left nostril floor (sball-snl)
7. Height of right nostril (ntr-nbr)
8. Height of left nostril (ntl-nbl)

3dMD angular measurements:

1. Nasolabial angle (c-sn-ls)
2. Inclination of right columella (acr-snr-cr)
3. Inclination of left columella (acl-snl-cl)
4. Inclination of right alar slope (prn-alr-all)
5. Inclination of left alar slope (prn-all-alr)

RESULTS

The distance between the alveolar cleft borders was 7 mm in beginning, but this gap was reduced through the treatment process. In the fourth week, the gap was 2.8 mm, and before surgery it was 1.4 mm (Table 1). The cleft width in the alveolar cleft area was considerably reduced in the early periods of treatment, and toward the end of the treatment it remained more stable. The vertical growth of the right and left columella lengths were increased, and the inclination of the columella was made steeper during the treatment period. These increases occurred because of the nasal molding treatment. The lengths of the right and left ala lengths remained similar to their initial values (Tables 1 and 2).

The nasal tip, which was leaning toward the cleft segment, was erected using a NAM appliance, and the lifting changed the inclination of the columella. The width of the left nostril floor was 11.48 mm at the beginning, but the elastic bands and surgery

Table 1. Linear dental and facial measurements (mm)

	Beginning (T1)	4th Weeks (T2)	5th Month (Pre surgery) (T3)	6th Month (Post surgery) (T4)
Width of alveolar gap	7.0	2.8	1.4	1.2
Width of palatal cleft	19.60	18.7	17.5	17.1
Right columella length	2.30	2.86	3.06	3.58
Left columella length	1.88	2.15	3.70	3.82
Right ala length	15.45	15.96	15.68	16.62
Left ala length	16.20	18.23	19.04	18.11
Right nostril floor width	6.55	6.32	6.83	7.03
Left nostril floor width	11.48	11.26	10.39	7.35
Right nostril height	4.01	4.55	4.52	6.17
Left nostril height	1.30	3.64	5.43	6.77

reduced it to 7.35 mm. Similar improvement was seen in the height of the left nostril, which was 1.30 mm before treatment and 6.77 mm after surgery. However, the width of the right nostril floor and height of the right nostril did not change remarkably compared with the left (Table 1).

DISCUSSION

ABS is a rare fetal malformation. It can be identified prenatally by ultrasound, which can sometimes show amniotic bands but frequently indicates malformations consistent with ABS as well as with oligoamnios and a reduction of fetal movements.¹⁴ In the second trimester of pregnancy, most ABS defects can be seen during routine ultrasound examinations.¹⁴ In this case, the infant's mother was under the regular care of a physician and received routine ultrasound examinations throughout her pregnancy. CLP was detected at the fourth month, but ABS was not found.

Amniotic rupture that occurs in the early periods of a pregnancy, especially during the first 45 days, leads to the most severe craniofacial and visceral malformations.⁵ However, every part of the fetal body can be affected, especially the upper extremities and digits. Cardiac and visceral malformations and brain and renal anomalies are less frequently seen with this syndrome, and in such cases patients with ABS should have ultrasound examinations of the head, heart, and abdomen.³⁻⁵ The patient was

evaluated by general surgery, plastic surgery, internal medicine, neurology, and pediatric clinics, and no problem was found.

In this case, the amniotic rupture resulted in CLP, and we applied a presurgical nutrition plate and NAM treatment. These treatment protocols help with nutrition and with shaping of nasoalveolar tissues and should be started immediately after birth because the degree of plasticity in neonatal cartilage is greatest at this time and gradually reduces as the infant grows.¹⁵

The ultimate goals of the presurgical nutrition plate and the NAM treatment are to reshape the nasal cartilage gradually, to lengthen the columella, and to reduce the width of the cleft area.¹¹ Therefore, the NAM treatment decreases the need for alveolar bone graft by reducing the alveolar gap.¹⁶ In our study, right columella inclination gradually decreased from T1 to T4, while left columella inclination (cleft side) increased and both columella lengths increased. Left and right alar slope inclinations were steeper. Both nostril floor widths decreased, and both nostril heights increased. These results indicate that the columella was more upright, the nose was narrower and longer, and nasal projection also improved at the end of treatment.

The NAM treatment protocol approximated the cleft alveolar segments and the lip segments. This treatment, then, facilitated the surgical operation of the lips and the cleft alveolar segments by keeping the lip and alveolar segments under minimal tension. In our study,

Table 2. Angular facial measurements

	Beginning (T1)	4th Weeks (T2)	5th Month (Pre surgery) (T3)	6th Month (Post surgery) (T4)
Nasolabial angle	135.44°	134.72°	132.93°	125.42°
Right columella inclination	102.68°	95.25°	91.28°	84.28°
Left columella inclination	70.68°	73.62°	72.32°	77.10°
Right alar slope inclination	24.99°	34.35°	36.90°	34.79°
Left alar slope inclination	25.34°	27.59°	29.00°	33.85°

the width of the left nostril floor (cleft side) was reduced from 11.48 mm to 10.39 mm and the width of the alveolar gap decreased from 7 mm to 1.4 mm from the beginning to the fifth month of treatment (Table 1).

At the beginning of the treatment, the nose of this patient with unilateral CLP showed asymmetry in terms of the width and height of the nostril floor and height and inclination of the columella. After 6 months of treatment, significant improvement had been achieved in all of these asymmetric structures. The 3dMD system was used in the study because it is quick, has the ability to image from multiple viewpoints, and is noninvasive and nonionizing.¹¹

ABS is not a clearly defined clinical condition, partly because of its controversial etiologies and the many synonyms used to describe it. However, eliminating chromosomopathies in ABS cases is of great importance because of the need to inform parents of the risk of future recurrence, which is very low for ABS.¹⁷

This syndrome is rarely hereditary because it is not associated with any genetic or chromosomal disorders.² Therefore, in general there is no recurrence in siblings or the children of affected adults. However, in cases where ABS is associated with genetic disorders, genetic testing should be applied. In our case, the absence of ABS in the parents, sibling, and twin brother of the patient reduces the likelihood of genetic transmission.

Recently, there have been some efforts to treat ABS prenatally through fetoscopic laser cutting of the amniotic bands before their compression on the fetus causes malformations.¹⁸

CONCLUSION

Orthodontists should be aware that CLP may be seen in patients with ABS, and in these circumstances they should immediately be treated with presurgical nutrition plates and NAM treatment protocols. If cardiac, visceral, brain, and renal anomalies present in these patients, orthodontists should consult relevant medical departments. Further research involving genetic analysis may be necessary to understand the pathogenesis of ABS, and in patients with ABS, genetic tests should be applied because of the need to inform parents of the risk of future recurrence.

REFERENCES

1. Tadmor O, Kreisbe G, Achiront R, Porat S, Yagel S. Limb amputation in amniotic band syndrome: serial ultrasono-

- graphic and Doppler observations. *Ultrasound Obstet Gynecol.* 1997;10:312–315.
2. Walter Jr JH, Goss LR, Lazzara AT. Amniotic band syndrome. *J Foot Ankle Surg.* 1998;37:325–333.
3. Bamforth JS. Amniotic band sequence: Streeter's hypothesis reexamined. *Am J Med Genet.* 1992;44:280–287.
4. Foulkes GD, Reinker K. Congenital constriction band syndrome: a seventy-year experience. *J Pediatr Orthop.* 1994;14:242–248.
5. Jabor MA, Cronin ED. Bilateral cleft lip and palate and limb deformities: a presentation of amniotic band sequence? *J Craniofac Surg.* 2000;11:388–393.
6. Higginbottom MC, Jones KL, Hall BD, Smith DW. The amniotic band disruption complex: timing of amniotic rupture and variable spectra of consequent defects. *J Pediatr.* 1979; 95:544–549.
7. Torpin R. Fetal malformations caused by amnion rupture during gestation. Charles C Thomas, Springfield, Illinois; 1968:1–76.
8. Weinzweig N. Constriction band-induced vascular compromise of the foot: classification and management of the "intermediate" Stage of Constriction-ring syndrome. *Plast Reconstr Surg.* 1995;96:972–977.
9. Seeds JW, Cefalo RC, Herbert WN. Amniotic band syndrome. *Am J Obstet Gynecol.* 1982;144:243–248.
10. Garza A, Cordero JF, Mulinare J. Epidemiology of the early amnion rupture spectrum of defects. *Am J Dis Child.* 1988; 142:541–544.
11. Grayson BH, Santiago PE, Brecht LE, Cutting CB. Presurgical nasoalveolar molding in infants with cleft lip and palate. *Cleft Palate Craniofac J.* 1999;36:486–498.
12. Lübbers H-T, Medinger L, Kruse A, Grätz KW, Matthews F. Precision and accuracy of the 3dMD photogrammetric system in craniomaxillofacial application. *J Craniofac Surg.* 2010;21:763–767.
13. Farkas L. *Anthropometry of the Head and Face.* 2nd ed. New York: Raven Press; 1994: 3–77.
14. Allen LM, Silverman RK, Nosovitch JT, Lohnes TM, Williams KD. Constriction rings and congenital amputations of the fingers and toes in a mild case of amniotic band syndrome. *J Diagn Med Sonogr.* 2007;23:280–285.
15. Matsuo K, Hirose T, Tomono T, Iwasawa M, Katohda S. Nonsurgical correction of congenital auricular deformities in the early neonate: a preliminary report. *Plast Reconstr Surg.* 1984;73:38–50.
16. Santiago PE, Grayson BH, Cutting CB, Gianoutsos MP, Brecht LE, Kwon SM. Reduced need for alveolar bone grafting by presurgical orthopedics and primary gingivoperiosteoplasty. *Cleft Palate Craniofac J.* 1998;35:77–80.
17. Bower C, Norwood F, Knowles S, Chambers H, Haan E, Chan A. Amniotic band syndrome: a population-based study in two Australian states. *Paediatr Perinat Epidemiol.* 1993;7: 395–403.
18. Quintero R, Morales W, Phillips J, Kalter C, Angel J. In utero lysis of amniotic bands. *Ultrasound Obstet Gynecol.* 1997; 10:316–320.